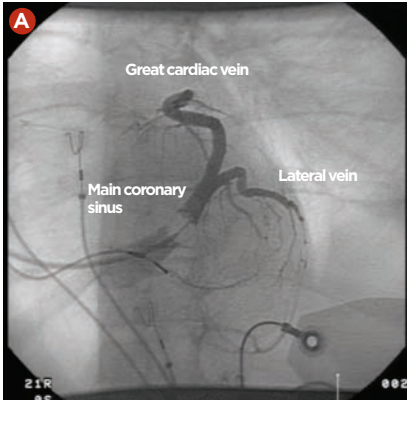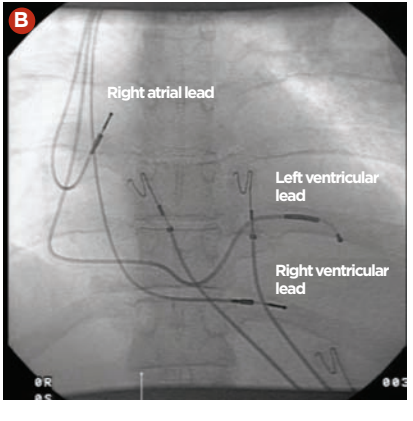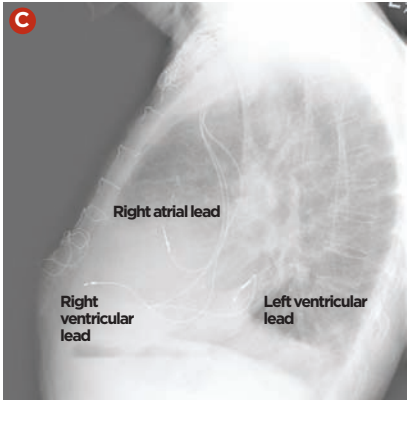FIGURE 5 CRT:
a) Contrast venogram of coronary sinus showing lateral vein suitable for left ventricular lead placement
b) AP chest fluoroscopy image showing right ventricular, right atrial and left ventricular leads in position
c) Lateral chest radiograph showing right ventricular, right atrial and left ventricular leads in position