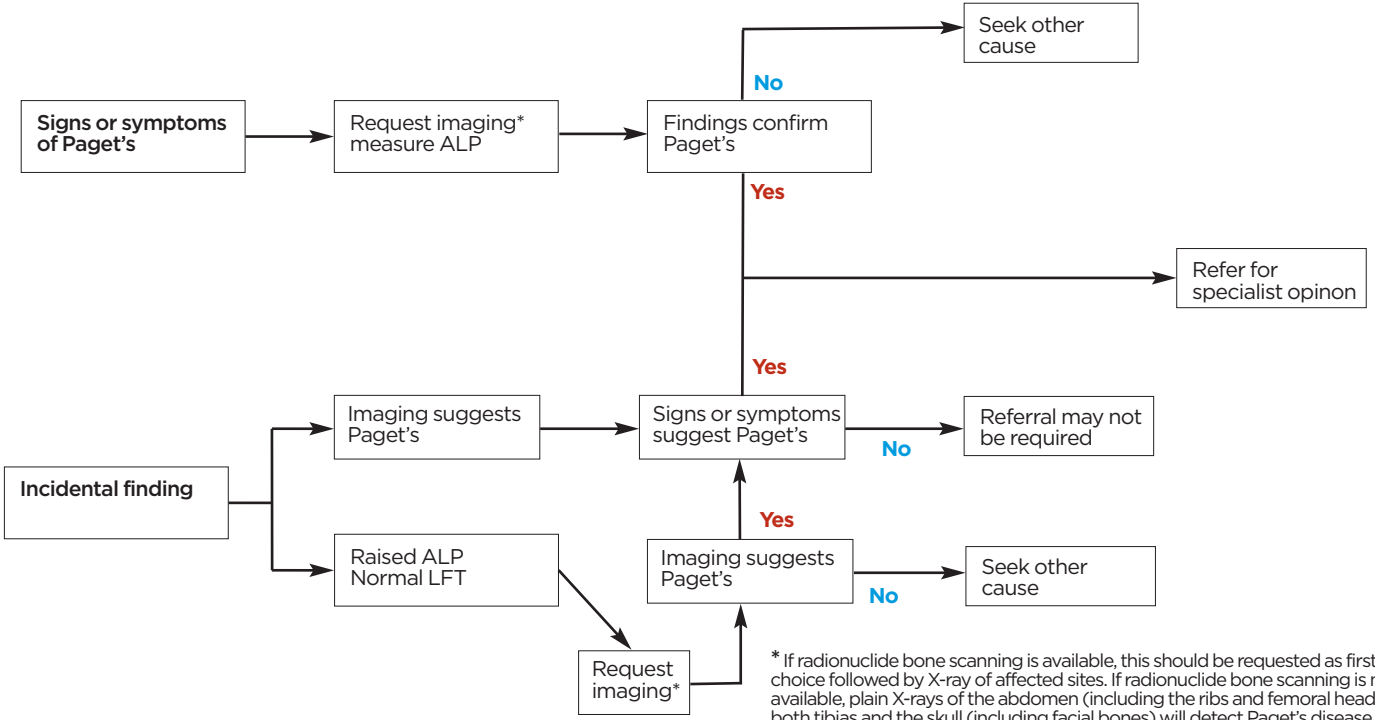

* If radionuclide bone scanning is available, this should be requested as first choice followed by X-ray of affected sites. If radionuclide bone scanning is not available, plain X-rays of the abdomen (including the ribs and femoral heads), both tibias and the skull (including facial bones) will detect Paget's disease in 93% of cases