

Palpitations: when you hear hoof beats don't forget to think zebras

Harskamp RE, Thole OB, Boeting J, Moggre J.

Palpitations: when you hear hoof beats don't forget to think zebras.

Practitioner 2017;261(1803):23-25

Dr Ralf E. Harskamp
MD PhD
GP Trainee¹ and Postdoctoral Researcher²

Dr Odile B. Thole
MD
General Practitioner¹

Dr Janne Boeting
MD
General Practitioner¹

Dr Izaak Moggré
MD
General Practitioner¹

¹Medisch Centrum Seinhorst, Hilversum

²Dept of General Practice, Academic Medical Centre,
Amsterdam,
The Netherlands



Practitioner
Medical Publishing Ltd

Palpitations: when you hear hoof beats don't forget to think zebras

AUTHORS

Dr Ralf E. Harskamp
MD PhD
GP Trainee¹ and
Postdoctoral Researcher²

Dr Odile B. Thole
MD
General Practitioner¹

Dr Janne Boeting
MD
General Practitioner¹

Dr Izaäk Moggré
MD
General Practitioner¹

¹Medisch Centrum
Seinhorst, Hilversum

²Dept of General Practice,
Academic Medical Centre,
Amsterdam,
The Netherlands

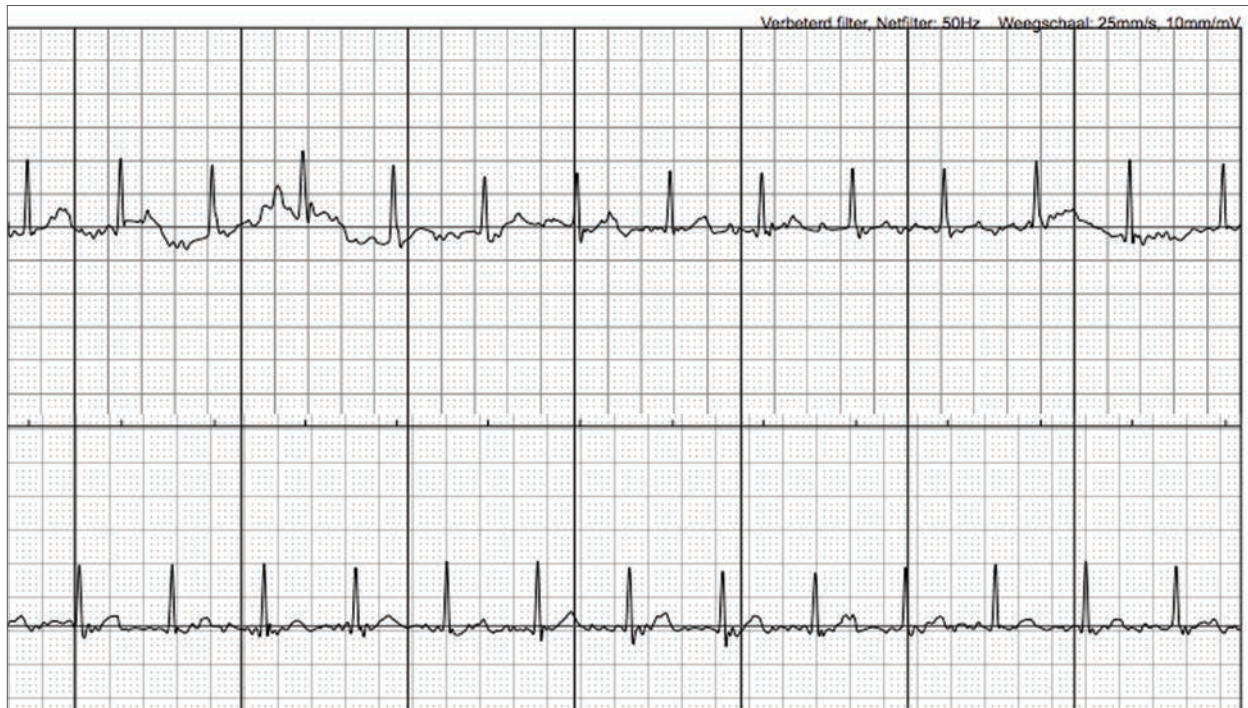


FIGURE 1

A smartphone-operated 1-lead ECG revealed a regular small complex tachycardia lacking P waves

How did the patient present in primary care?



A 62-YEAR-OLD MAN PRESENTED WITH RECURRENT SYMPTOMS OF PALPITATIONS AND

lightheadedness over the past few months.

Symptoms occurred paroxysmally, had sudden onset and termination, with the longest episode lasting 1.5 hours. He had an active lifestyle, did not smoke and worked as a commercial bus driver.

His past medical history and family history were unremarkable. At the time of presentation he was not experiencing any symptoms. Physical examination as well as a 12-lead electrocardiogram (ECG) and laboratory work-up were unremarkable.

The patient was instructed to return to our practice when experiencing symptoms. Several days later the patient presented again, this time with palpitations.

What investigations were carried out?

DIAGNOSIS

On physical examination a tachycardic, regular pulse was found. Blood pressure was normal. A smartphone-operated 1-lead ECG device was used to allow for a 30-second rhythm recording and analysis to rule out atrial fibrillation (AF).

As shown in figure 1, above, a regular small complex tachycardia was revealed lacking P waves. The automatic algorithm reported the arrhythmia as non-classified, indicating it was not AF or sinus tachycardia.

Subsequently a 12-lead ECG was performed showing a small complex tachycardia, with a P wave buried at the end of the QRS complex, see figure 2, p24.

The differential diagnosis of a regular narrow complex tachycardia with a buried P wave includes atrioventricular re-entry tachycardia (AVRT) or AV nodal re-entry tachycardia (AVNRT).

How was the correct diagnosis made?

Both arrhythmias involve a re-entry circuit, either through an accessory pathway (AVRT) or within the AV node itself (AVNRT).

The Valsalva manoeuvre and carotid massage are non-invasive strategies that may terminate these arrhythmias. We performed these procedures but without effect. The patient was subsequently referred to a nearby hospital with a full cardiology service for further evaluation and termination with intravenous adenosine, a drug that affects the AV node.

The cardiologist reported back that the arrhythmia was an AVNRT. The use of verapamil 40 mg as a pill in the pocket was recommended to terminate future occurrence and a follow-up visit was scheduled. We advised the patient to contact the CBR (the Dutch driver licensing agency).

Thus far, the patient has had several >>

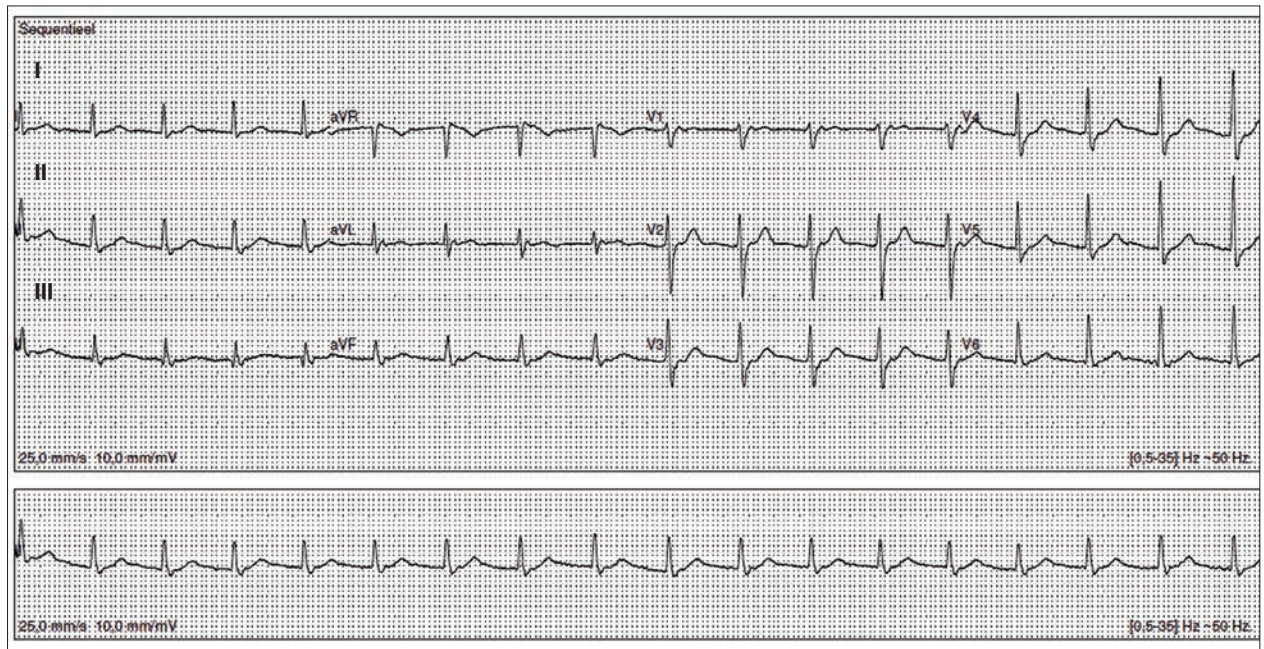


FIGURE 2
A 12-lead ECG showing a small complex tachycardia, with a P wave buried at the end of the QRS complex

more episodes of palpitations, with a good response on verapamil.

DISCUSSION

Palpitations are an unpleasant, pounding sensation in the chest and/or neck. In general practice, these symptoms are reported in approximately 8 per 1,000 persons per year, with the majority lacking an underlying cardiac cause.¹² As physicians we may very well only see the tip of the iceberg. This is illustrated by a telephone survey in New Zealand which reported that 71 out of 1,000 respondents (7.1%) reported palpitations or irregular heartbeat in the past seven days.³ The differential diagnosis includes cardiac and psychiatric causes, as well as numerous others (i.e. hyperthyroidism, anaemia, prescribed medications, caffeine, and recreational drugs).^{2,4}

Prior research shows that prediction of arrhythmias by family physicians based on history taking and physical examination alone is not accurate.⁵ However, careful history taking helps. Factors that point towards a cardiac aetiology for palpitations are: male sex, irregular heartbeat, history of heart disease, event duration > 5 minutes, frequent palpitations, palpitations which occur at work or disturb sleep.^{6,7} Other clues suggesting a cardiac origin are abrupt onset and termination of palpitations, positional palpitations, and accompanying symptoms such as dizziness and presyncope.

When considering a cardiac arrhythmia the age factor also comes into play. For instance AF or ventricular arrhythmias are far more common in

older patients as they are associated with structural heart disease, whereas palpitations in a younger person much more suggestive of a supraventricular tachycardia. Physical examination is helpful (and also in the absence of symptoms) to look for signs indicating structural heart disease, such as heart murmurs suggestive of valvular disease, and signs of heart failure.

‘The added value in this case was that besides indicating it was not AF, it also revealed a small complex tachycardia’

In the presented case, complete work-up was performed given the recurrent nature of symptoms, gender, sudden onset, event duration > 5 minutes and accompanying lightheadedness.

The availability of a 12-lead ECG in our practice certainly helped to lower the diagnostic threshold. To lower the diagnostic threshold for arrhythmia detection even further we recently introduced the use of a smartphone-operated 1-lead ECG device to aid in decision making (FDA-approved, CE-mark, by AliveCor Inc, Mountain View, California, and service operated by Livv Mobile Health, Zwolle, The Netherlands).

While the ECG device has been evaluated for AF,⁹ the added value in this case was that besides indicating it was

not AF, it also revealed a small complex tachycardia when visually analysing the rhythm strip.

A consultant electrophysiologist even made the diagnosis AVNRT based on the 30-second rhythm strip while blinded for the 12-lead ECG. In general, the main advantage of using this smartphone-based device primarily lies in the instant reassurance that it will give in the majority of patients in whom symptoms are not arrhythmic based and thereby saving unnecessary additional work-up. It may be a particularly attractive tool in practices without direct access to a 12-lead ECG, and in addition can also be given to patients, who at the time of presentation do not have symptoms, to take home to enable self-activated monitoring.

Cardiac arrhythmias are the result of enhanced automaticity, triggered activity or re-entry. The latter mechanism is responsible for the majority of clinically relevant arrhythmias, such as AF and supraventricular tachycardias. The prevalence of supraventricular tachycardia in the general population is approximately 2-3 per 1,000 persons. AVNRT is the most common paroxysmal supraventricular tachycardia, accounting for nearly two-thirds of all cases.⁹

In the presented case, AVNRT was diagnosed. AVNRT is the result of a dual intra-AV nodal electrical pathway. This dual pathway consists of a slow and fast pathway with a final common pathway at the proximal and distal AV junction.¹⁰ Typically these pathways can be triggered by a premature atrial beat. Most of the time the slow pathway gets

key points

SELECTED BY

Dr Phillip Bland
GP, Dalton-in-Furness, UK

In general practice palpitations are reported in approximately 8 per 1,000 persons per year. The differential diagnosis includes cardiac and psychiatric causes, as well as numerous others including hyperthyroidism, anaemia, prescribed medication, caffeine and recreational drugs.

Factors that point towards a cardiac aetiology are male sex, irregular heartbeat, history of heart disease, event duration > 5 minutes, frequent palpitations, and palpitations which occur at work or disturb sleep. Other clues suggesting a cardiac origin are abrupt onset and termination of palpitations, positional palpitations, and accompanying symptoms such as dizziness and presyncope.

Cardiac arrhythmias are the result of enhanced automaticity, triggered activity or re-entry. The latter mechanism is responsible for the majority of clinically relevant arrhythmias, such as atrial fibrillation and supraventricular tachycardias.

The prevalence of supraventricular tachycardia in the general population is around 2-3 per 1,000 persons. AV nodal re-entry tachycardia (AVNRT) is the most common paroxysmal supraventricular tachycardia, accounting for nearly two-thirds of all cases.

The typical clinical presentation of AVNRT is a sudden onset of palpitations (98%) and/or dizziness (78%). Patients may present at any age and are more frequently female than male. Providing there are no contraindications, the first step in acute management involves performing vagal manoeuvres that are effective in terminating supraventricular tachycardias and can be safely performed in primary care.

Case report submissions

Do you have an interesting case that you would like to share with other readers?

Your article would need to be around 1,500 words long, include a brief review of the literature to put the case in context, and be fully referenced in the Vancouver style.

Submissions for consideration for publication should be sent to: editor@thepractioner.co.uk

triggered because of its shorter refractory period. What happens next is that the premature beat is conducted antegrade down the slow pathway and when it reaches the common pathway the fast pathway is open and conduction subsequently occurs retrograde up the fast pathway again to the atria and within the AV node resulting in a sustained loop or re-entry tachycardia.

The typical clinical presentation of AVNRT is a sudden onset of palpitations (98%) and/or dizziness (78%).¹¹ Patients may present at any age and are more frequently female than male.^{12,13}

AVNRT is terminated with electrical cardioversion in haemodynamically unstable patients. In all other cases, vagal manoeuvres, such as the Valsalva manoeuvre or carotid sinus massage, should be performed first. Carotid massage should not be applied in patients with a recent CVA/TIA, myocardial infarction or carotid bruits. Vagal manoeuvres increase parasympathetic tone and result in slowing and blocking of the antegrade slow pathway.¹⁴ When this fails, as in our case, intravenous administration of medications that temporarily affect AV conduction are required. These include adenosine, calcium channel blockers, beta blockers or digoxin.

Long-term management of AVNRT depends on the frequency, duration and burden of recurring episodes, as well as the patient's tolerance of medications. Most frequently, patients choose a pill-in-the-pocket strategy without long-term antiarrhythmic medications. Catheter ablation to terminate AVNRT, either with radiofrequency or cryoablation, is highly effective, but at the cost of potential AV node damage and the patient requiring a pacemaker. The long-term success rate of radiofrequency ablation is significantly higher but at the potential expense of more permanent AV node block.¹⁵

CONCLUSION

Palpitations are common in primary care. While the odds of finding a relevant cardiac arrhythmia are low, the diagnostic threshold should be set low. In this case, the patient was found to have AVNRT.

Providing there are no contraindications, the first step in acute management involves performing vagal manoeuvres that are effective in terminating supraventricular tachycardias and can be safely performed in primary care. Overall, when dealing with a patient with palpitations, the emphasis should be on careful history taking to find

clues that suggest an underlying arrhythmia.

As patients are usually asymptomatic at consultation, they should be told to come for an ECG when symptoms do present.

A readily available smartphone-based 1-lead ECG may provide a welcome addition to our armamentarium, as it serves as a diagnostic tool either in the doctor's surgery, when performing house calls, or for ambulatory use to allow patients to activate themselves when experiencing symptoms.

REFERENCES

- 1 Thavendiranathan P, Bagai A, Koo C et al. Does this patient with palpitations have a cardiac arrhythmia? *JAMA* 2009;302:2135-43
- 2 Zwietering PJ, Knottnerus A, Gorgels T, Rinkens P. Occurrence of arrhythmias in general practice. *Scand J Prim Health Care* 1996;14:244-50
- 3 Petrie KJ, Faasse K, Crichton F, Grey A. How common are symptoms? Evidence from a New Zealand national telephone survey. *BMJ Open* 2014;4:e005374
- 4 Weber BE, Kapoor WN. Evaluation and outcomes of patients with palpitations. *Am J Med* 1996;100:138-48
- 5 Hoefman E, Boer KR, van Weert HC et al. Predictive value of history taking and physical examination in diagnosing arrhythmias in general practice. *Fam Pract* 2007;24:636-41
- 6 Hoefman E, van Weert HCPM, Reitsma JB et al. Diagnostic yield of patient-activated loop recorders for detecting heart rhythm abnormalities in general practice: a randomised clinical trial. *Fam Pract* 2005;22:478-84
- 7 Summerton N, Mann S, Rigby A et al. New-onset palpitations in general practice: assessing the discriminant value of items within the clinical history. *Fam Pract* 2001;18:383-92
- 8 Williams J, Pearce K, Bennett I. The effectiveness of a mobile ECGs device in identifying AF: sensitivity, specificity, and predictive value. *Br J Cardiol* 2015;22:70-72
- 9 Page RL, Joglar JA, Caldwell MA et al. 2015 ACC/AHA/HRS Guideline for the management of adult patients with supraventricular tachycardia: A report of the American College of Cardiology/American Heart Association Task Force on Clinical Practice Guidelines and the Heart Rhythm Society. *J Am Coll Cardiol* 2016;67:e27-e115
- 10 McGuire MA, Janse MJ, Rose DL. "AV nodal" reentry: Part II: AV nodal, AV junctional, or atrionodal reentry? *J Cardiovasc Electrophysiol* 1993;4:573-86
- 11 Wood KA, Drew BJ, Scheinman MM. Frequency of disabling symptoms in supraventricular tachycardia. *Am J Cardiol* 1997;79:145-49
- 12 Liuba I, Jönsson A, Säfsström K, Walfridsson H. Gender-related differences in patients with atrioventricular nodal reentry tachycardia. *Am J Cardiol* 2006;97:384-88
- 13 Goyal R, Zivin A, Souza J et al. Comparison of the ages of tachycardia onset in patients with atrioventricular nodal reentrant tachycardia and accessory pathway-mediated tachycardia. *Am Heart J* 1996;132:765-67
- 14 Pandya A, Lang E. Valsalva maneuver for termination of supraventricular tachycardia. *Ann Emerg Med* 2015; 65:27-29
- 15 Hanninen M, Yeung-Lai-Wah N, Massel D et al. Cryoablation versus RF ablation for AVNRT: a meta-analysis and systematic review. *J Cardiovasc Electrophysiol* 2013;24:1354-60

We welcome your feedback

If you wish to comment on this article or have a question for the authors, write to: editor@thepractioner.co.uk