Fingers and toes

AUTHOR
Dr Nigel Stollery
MB BS DPD
GP, Kibworth, Leicestershire and clinical assistant in dermatology, Leicester Royal Infirmary

Paronychia

Paronychia is an infection of the soft tissue around the nail. In acute cases such as this, trauma to the area is followed by the development of redness, warmth and pain over a few days after which pus will often be seen under the skin in the affected area. Incision and drainage followed by a course of oral antibiotics is the treatment of choice. Soaking in warm water three or four times a day may also help.

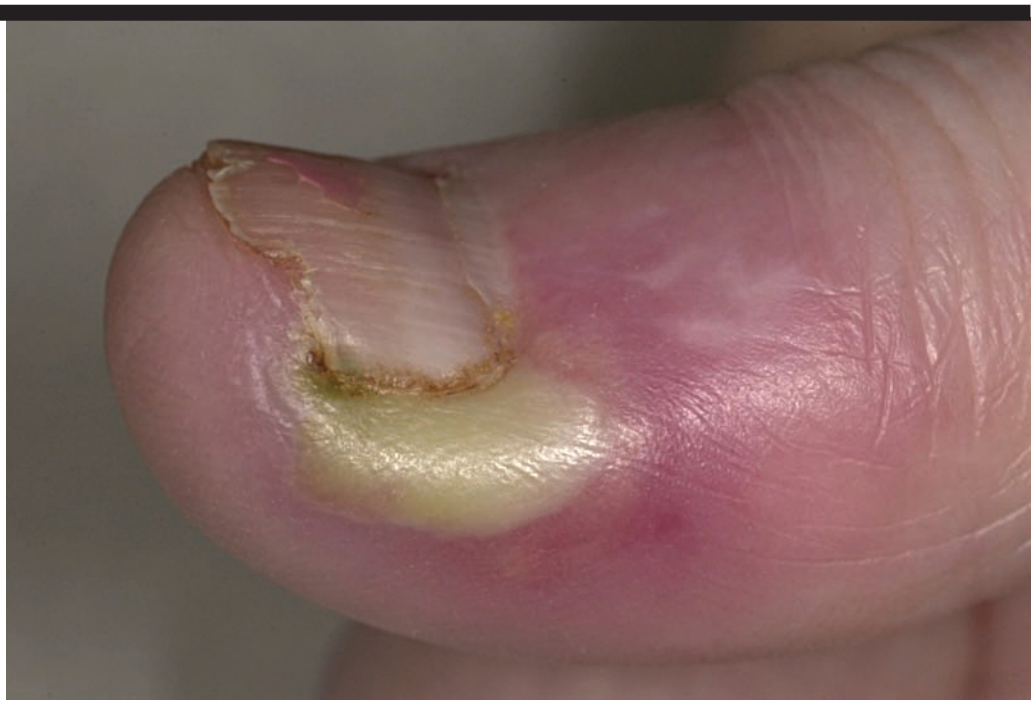

Verruca

Verrucas, and hand warts, are caused by HPV infection. They are very common, 7-12% of the population are thought to be affected at any one time (10-20% of schoolchildren). Verrucas have an equal distribution between the sexes. Peak incidence occurs in children aged 12 to 16 years. Infection is spread by direct or indirect contact, especially in showers and swimming pools. The incubation period is one to six months. Treatment options include topical salicylic acid, cryotherapy, and occlusion with duct tape. In severe, resistant cases intralesional injection with bleomycin can be tried, but cure rates vary from 33 to 92%. However, treatment is not always necessary as most lesions will usually clear with time.



»

Raynaud's phenomenon



Named after Maurice Raynaud who first described the phenomenon as a medical student in 1862, this condition occurs as a result of recurrent vasospasm in the fingers and toes secondary to stress or cold exposure. It is more common in women and in the second and third decades of life. The cause of the primary condition remains unknown. Secondary Raynaud's may be associated with a variety of conditions such as rheumatoid arthritis, myeloma and hepatitis B and C. Treatment includes general warming measures such as wearing heated gloves and thermal socks. Vasoconstricting medications such as beta-blockers should be avoided. In severe cases, medical treatment may be considered with calcium channel blockers, ACE inhibitors or topical GTN.

Chilblains



Chilblains are painful, pruritic, purple/violet inflammatory skin lesions which occur as a result of exposure to cold. They usually affect toes and fingers but in horse riders may also occur on the thighs. Women are more commonly affected than men. Peak incidence is in young to middle age, although children and the elderly can also be affected. Diagnosis can usually be made by taking a detailed history and careful examination. In secondary cases there may be an underlying cause such as antiphospholipid syndrome, anorexia nervosa or coeliac disease. Treatment initially involves advice about keeping affected areas warm. In more severe cases, ultraviolet light treatment at the beginning of winter and medications such as calcium channel blockers can be helpful.

Pyogenic granuloma

Pyogenic granulomas are benign vascular lesions of the skin. The cause is unknown. They usually occur in children and young adults as shiny red papules that bleed easily. The lesions most often affect the head, extremities and upper trunk, typically growing rapidly over a few weeks. Excision or curettage and cautery is usually undertaken as the lesions tend to cause bleeding and discomfort, and their cosmetic appearance can cause distress. The most serious differential diagnosis is squamous cell carcinoma so it is advisable to send any excised tissue for histological examination.

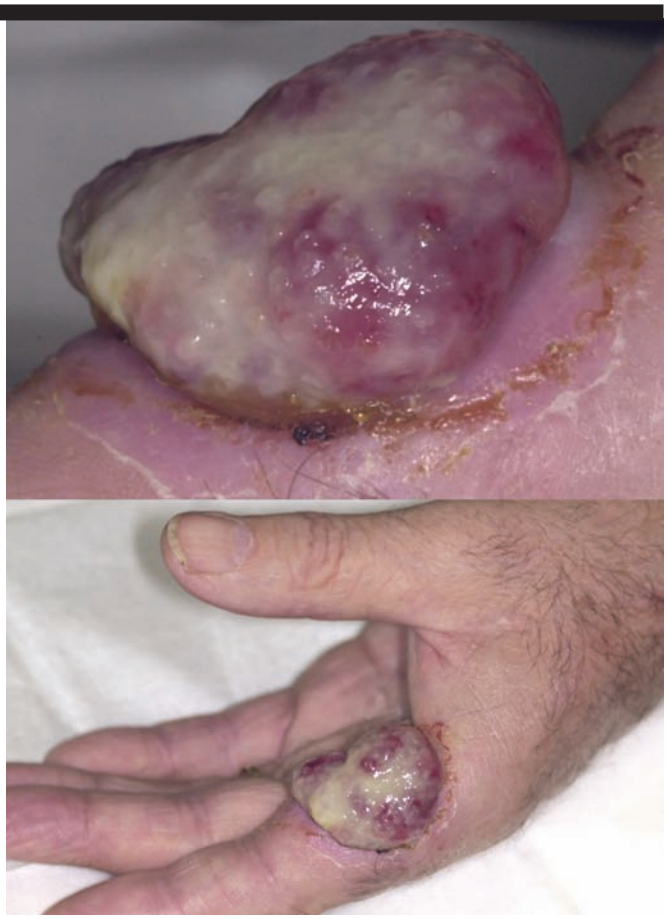

Ganglion

Ganglions are the most common soft tissue tumours of the hands and wrist, and are thought to occur as an outpouching of synovium from an adjacent joint. They vary in size and in most cases are not painful. Treatment is usually requested because the swelling is in a very visible location. Options vary from compression to bursting the cyst (at one time performed by striking the swelling with the family Bible), simple aspiration, or full formal surgical excision.

