Scalp problems

AUTHOR
Dr Nigel Stollery
MB BS DPD
GP, Kibworth, Leicestershire and clinical assistant in dermatology, Leicester Royal Infirmary

Impetigo

Impetigo is a bacterial skin infection caused by streptococcus or *Staphylococcus aureus*. It can affect any area of the body including the scalp. Trauma to the skin such as repeated scratching can predispose to the condition. Impetigo on the scalp may be preceded by infestation with head lice. Transient alopecia may also occur. Impetigo can be treated with oral antibiotics.

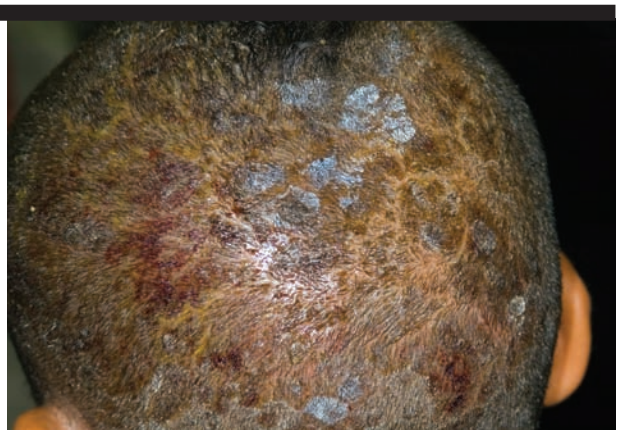

Alopecia areata

The psychological impact of alopecia must never be underestimated especially when the area affected is extensive. The condition may be associated with other immunological conditions such as thyroid disease, vitiligo and atopy. In some cases it may occur following emotional trauma. It is relatively common affecting 2% of patients seen in dermatology outpatient departments. Treatments include: topical steroids; diphencyprone, PUVA and intralesional injection with triamcinolone. Some patients may wish to consider wearing a wig.



Male pattern baldness

Male pattern or androgenic baldness is a very common and often hereditary condition in which the hair is lost from the temples and the crown. The diagnosis is usually straightforward and does not require any investigations. Treatment options include scalp surgery, hair transplants, topical minoxidil and oral finasteride. However, none of these is particularly effective.



Actinic keratoses

Actinic keratoses are discrete lesions with a rough surface, that occur on sun-damaged skin. As such they are more commonly found on the scalp, face, hands and forearms. Differential diagnoses include: seborrhoeic keratoses which have a 'stuck on' appearance; viral warts; and squamous cell carcinoma. Treatment includes cryotherapy, curettage and cautery, topical NSAID gel, 5 fluorouracil and imiquimod. Any lesion which fails to respond to these treatments should be biopsied to exclude an underlying squamous cell carcinoma.



Scalp psoriasis

As well as affecting the skin, nails and joints psoriasis can also affect the scalp giving rise to a thick layer of scale. When you are trying to decide whether a scaly scalp is caused by psoriasis look at the edges of the plaques which are usually very well demarcated and surrounded by normal skin. The areas affected are also thickened and can be felt more easily than seen. Scalp psoriasis can be treated with emollients, tar preparations, topical steroids and vitamin D_3 analogues.



Pigmented basal cell carcinoma

Basal cell carcinomas (BCCs) can be divided into four basic types: nodular-ulcerative; cystic; morphoeic and superficial. In any of these four types pigment may be present which is often speckled through the lesion. In this case the lesion is a nodular BCC which is commonly found on the scalp. Treatment options include excision, Mohs surgery for complex or recurrent lesions, photodynamic therapy, imiquimod and radiotherapy.

